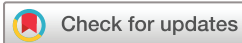

Phase 1B study of the safety and tolerability of the mineralocorticoid fludrocortisone acetate in patients with geographical atrophy

Thomas Hong ,¹ Andrew Chang,^{1,2} Ted Maddess,³ Jan Provis,^{4,5} Philip Penfold^{5,6}

To cite: Hong T, Chang A, Maddess T, *et al*. Phase 1B study of the safety and tolerability of the mineralocorticoid fludrocortisone acetate in patients with geographical atrophy. *BMJ Open Ophthalmology* 2022;**0**:e001032. doi:10.1136/bmjophth-2022-001032

Received 5 April 2022
Accepted 10 June 2022



© Author(s) (or their employer(s)) 2022. Re-use permitted under CC BY-NC. No commercial re-use. See rights and permissions. Published by BMJ.

¹CUREOS, Acurio Health, Sydney, New South Wales, Australia

²The University of Sydney Save Sight Institute, Sydney, New South Wales, Australia

³ARC Centre of Excellence in Vision Science, Australian National University, Canberra, Australian Capital Territory, Australia

⁴Eccles Institute of Neuroscience, Australian National University, Canberra, Australian Capital Territory, Australia

⁵Eye Co Pty Ltd, Balwyn North, Victoria, Australia

⁶Australian National University, Canberra, Australian Capital Territory, Australia

Correspondence to

Dr Thomas Hong;
thomashong@gmail.com

ABSTRACT

Objective To evaluate the safety and tolerability of a mineralocorticoid, in a single-dose intravitreal (IVT) injection of 1 mg/0.1 mL and 2 mg/0.1 mL fludrocortisone acetate (FCA) in subjects with geographical atrophy (GA) secondary to age-related macular degeneration.

Methods and Analysis This phase 1b study was a two-part dose-escalation prospective study. Part 1 involved a single participant treated with 1 mg/0.1 mL and monitored up to 28 days before being reviewed by a safety review committee. Two subsequent participants were then dosed with the same dose. Part 2 involved a single participant dosed with 2 mg/0.1 mL and monitored up to 28 days when a further five participants were dosed. All participants were followed up for 6 months after baseline. A full ophthalmic assessment was performed at study visits which included GA area, best-corrected visual acuity (BCVA), low-luminance BCVA (LL-BCVA) and intraocular pressure (IOP). Adverse events (AEs) were reported from the first dose of FCA until the end-of-study visit.

Results There were no serious AEs (ocular or systemic) observed with IVT FCA at either 1 mg/0.1 mL or 2 mg/0.1 mL among nine participants. There was no evidence of increased IOP or cataract development. Neither BCVA or LL-BCVA changed significantly in the study-eye over the follow-up period ($p=0.28$ and 0.38 , respectively). Mean GA area increased in the study (0.5 mm^2 , $p=0.003$) and fellow-eyes (0.62 mm^2 , $p=0.02$) over 6 months. Differences between eyes were not significant ($p=0.64$), and at the lower end of population norms.

Conclusion IVT FCA is clinically safe and well tolerated and did not increase IOP.

INTRODUCTION

Steroids are commonly used to treat retinal disease such as diabetic macular oedema¹ and retinal vein occlusions² as either sole or combination therapy. These steroids have mostly been glucocorticoids which have been shown to have side effects including a raised intraocular pressure (IOP) and lens opacification.³

Fludrocortisone acetate (FCA) ($9\text{-}\alpha\text{-Fluoro-11}\beta\text{-17}\alpha\text{-21-trihydroxy-4-pregnene-3,20-dione acetate}$, FCA) is a synthetic steroid possessing a potent mineralocorticoid effect and high glucocorticoid activity,⁴ and so has anti-inflammatory and antiexudative properties. FCA is a mineralocorticoid receptor and glucocorticoid receptor agonist that binds to cytoplasmic receptors, translocates to the nucleus and subsequently initiates the transcription of glucocorticoid-responsive genes such as lipocortins to inhibit phospholipase A2. This prevents the release of arachidonic acid, a precursor to prostaglandins and leukotrienes, both important mediators in the proinflammatory response mechanism. In addition, this agent exerts its mineralocorticoid effect on the distal tubules and

WHAT IS ALREADY KNOWN ON THIS TOPIC

⇒ Currently, there are no approved therapies for geographical atrophy. Many therapies are being explored to target different pathways including complement inhibitors. This study assesses the use of a steroid to reduce inflammation, which has been associated with age-related macular degeneration.

WHAT THIS STUDY ADDS

⇒ Steroids may offer an alternate treatment option in geographical atrophy. This study suggests that fludrocortisone acetate may be a feasible therapy for reducing the progression of geographical atrophy without the typical side effects associated with steroids.

HOW THIS STUDY MIGHT AFFECT RESEARCH, PRACTICE OR POLICY

⇒ Previously reported studies using intravitreal complement inhibitors have been administered either every month or every other month. Currently, treatment with steroids is less frequent dependent on delivery methods and the half-life of the drug but are typically given every 3–6 months. Less frequent treatments with steroids for geographical atrophy may reduce the treatment burden on affected individuals.

20 dione acetate, FCA) is a synthetic steroid possessing a potent mineralocorticoid effect and high glucocorticoid activity,⁴ and so has anti-inflammatory and antiexudative properties. FCA is a mineralocorticoid receptor and glucocorticoid receptor agonist that binds to cytoplasmic receptors, translocates to the nucleus and subsequently initiates the transcription of glucocorticoid-responsive genes such as lipocortins to inhibit phospholipase A2. This prevents the release of arachidonic acid, a precursor to prostaglandins and leukotrienes, both important mediators in the proinflammatory response mechanism. In addition, this agent exerts its mineralocorticoid effect on the distal tubules and

collecting ducts of the kidney by inducing permease, an enzyme that regulates Na⁺ permeability in cells, thereby enhancing Na⁺ reabsorption and water retention as well as increasing K⁺, H⁺ excretion.

Previous preclinical studies have indicated that FCA showed neuroprotective properties in mice, with a preservation of the outer nuclear layer in the retina of mice with induced photo-oxidative damage compared with triamcinolone acetonide and control eyes. Furthermore, the a-wave and b-wave response on electroretinography was higher than comparator arms suggesting preservation of photoreceptors.⁵ Furthermore, a study in rabbits found that intravitreal (IVT) FCA did not increase IOP.⁶

Age-related macular degeneration (AMD) is the leading cause of severe vision loss in people over the age of 65 in Western countries.⁷ In the USA, about 1.75 million people have the advanced forms of AMD.^{8,9} The early signs of AMD (drusen and pigmentary changes) are common in individuals over age 65 and precede the advanced forms, which are visually devastating. The advanced forms of AMD are classified into either choroidal neovascularisation (CNV) (wet or exudative) or geographical atrophy (GA) (dry).

GA is a disease characterised by thinning and loss of the retinal pigment epithelium (RPE), and concurrent atrophy of photoreceptors and choriocapillaris.¹⁰ Clinically, GA is characterised by islands of dead retinal cells in the back of the eye that gradually expand. Although GA can result in significant visual function deficits in reading, night vision, and dark adaptation, and produce dense, irreversible scotomas in the visual field, the initial decline in VA may be relatively limited if the fovea is spared. When the fovea is involved, GA quickly causes blindness. GA is responsible for approximately 20% of all legal cases of blindness in North America with increasing incidence and prevalence owing to a higher life expectancy.¹¹

AMD is a highly complex disease that is affected by multiple factors, such as ageing, genetic predisposition, environmental elements, oxidative stress and inflammatory effects.^{8,12,13} Smoking, age, alcohol consumption, diet and obesity are important risk factors related to oxidative stress.^{13,14} High body mass index, cardiovascular disease, hypertension and a variety of dietary patterns are risk factors less consistently.¹⁵ Several single-nucleotide polymorphisms that confer increased or decreased risk of inflammation have been identified. They include the well-recognised complement factor H, CX3CR1, Toll-like receptor 3 (TLR3), TLR4 and interleukin 8 (IL-8).¹⁶

Although AMD is not a classic inflammatory disease, inflammatory cells have an important role in AMD pathogenesis and progression.^{12,17,18} Evidence has also suggested that some infectious agents are associated with AMD. Interleukin 6 (IL-6) has also been found to be upregulated in neovascular AMD and GA, furthermore it has been linked to GA progression.¹⁹

The purpose of this study was to assess the safety and tolerability of a single IVT dose of FCA among patients with GA over a 6-month period.

METHODS

Study design

This single-centre, phase 1b prospective, open-labelled, single-dose, dose-escalation clinical trial was conducted on nine participants enrolled at a single site between August 2019 and April 2021 at an eye clinic in Sydney, Australia. All patients were followed up for 6 months after baseline. Ethics approval was obtained before commencement and the trial was listed on the Australian and New Zealand Clinical Trial Registry (accessible via www.anzctr.org.au; ANZCTR no. 12618001308280). An independent data and safety committee provided oversight of the clinical trial. This study adhered to the tenets of the Declaration of Helsinki. Informed consent was obtained from all participants before enrolment into the study.

Study medication

FCA was formulated for IVT administration as a powder solution for injection to ensure long-term stability similar to other corticosteroids.²⁰ Vials contained 10 mg of FCA powder and were reconstituted with sterile sodium chloride solution (0.9%) according to the appropriate dosage prior to injection.

Study population

Inclusion criteria referring the study eye were as follows: diagnosis of GA secondary to AMD confirmed using fundus autofluorescence (FAF) imaging, GA area between ≥ 1.9 and ≤ 17 mm² (1-disc and 7-disc areas, respectively), best-corrected visual acuity (BCVA) of 24 letters or better using Early Treatment Diabetic Retinopathy Study (ETDRS) charts.

Exclusion criteria were as follows: GA due to causes other than AMD such as Stargardt disease, cone rod dystrophy or toxic maculopathies like plaquenil maculopathy, spherical equivalent of the refractive error demonstrating >6 dioptres of myopia or an axial length of >26 mm, evidence or history of exudative (wet) AMD including evidence of RPE tears or evidence of neovascularisation anywhere in the retina based on fluorescein angiogram in either eye within 12 months, retinal disease likely to confound visual performance or be affected by intraocular steroid, intraocular surgery (including lens replacement surgery) within 3 months prior to dosing, aphakia or absence of the posterior capsule, previous violation of the posterior capsule is also excluded unless it occurred as a result of yttrium aluminium garnet laser posterior capsulotomy in association with prior posterior chamber intraocular lens implantation and at least 60 days prior to day 0, glaucoma or family history of glaucoma, any contraindication of IVT injection including current ocular or periocular infection, history of uveitis

or endophthalmitis, history of IVT injection within 12 months.

If both eyes met the criteria, the eye with the best VA at the screening visit was designated as the study eye.

Study protocol

A full ophthalmic assessment was performed at each study visit which included GA area assessed through FAF imaging, BCVA, lower-luminance BCVA (LL-BCVA) and IOP. Participants were assessed at screening, baseline, day 1, day 7, day 14, day 28, day 60, day 90 and day 150 (end of study). Blood and urine samples were collected for safety analysis at screening, baseline, day 7, day 28 and day 150.

Part 1 of the study involved a single participant treated with 1 mg/0.1 mL FCA to assess safety and tolerability. This participant was followed up for 28 days before the results were reviewed by an independent data safety monitoring committee (DSMB). Subsequent to approval by the DSMB, a further two participants were treated with 1 mg/0.1 mL FCA and followed up for a further 28 days after treatment before commencement of part 2.

Part 2 involved a single dose of 2 mg/0.1 mL of FCA in a single participant and followed up for 28 days like part 1. The DSMB reviewed the results prior to enrolment of the remaining five participants.

Outcome measures

Fundus autofluorescence was captured using Heidelberg Spectralis (Heidelberg Engineering, Heidelberg, Germany). The assessment of GA size and progression was performed using FAF was performed by two graders (TH and AC) in a blinded manner using Heidelberg

region finder software V.2.6.2.0 (figure 1), a semiautomated programme used to quantify atrophic areas. Baseline FAF images were defined and used to assess subsequent visits using the region finder software. In cases where there was a discrepancy of more than 20% between the two graders, a third grader (AC) evaluated the images. Areas of peripapillary atrophy were not included in the measurements. GA was defined as well-demarcated regions of hypofluorescence on FAF from the absence of the RPE layer over the neurosensory retina.

BCVA was assessed at every study visit at 4 m using an ETDRS chart following subjective refraction. LL-BCVA was assessed similarly with a neutral density lens. IOP was assessed with Goldmann applanation tonometry. Adverse events (AEs) were reported from the first dose of FCA in the first patient until the last patient last visit.

Statistical analysis

Statistical analysis was performed using SPSS software V.24.0 (SPSS) and are primarily descriptive. Summaries of safety data are presented in the results. Descriptive statistics (mean, SD, median, minimum and maximum) are calculated for summaries of continuous data. Paired t-tests were performed to assess change from baseline and two sampled t-tests were performed to compare change between eyes. As this was a phase 1B study, there was no formal sample size calculation.

Safety data, including vital signs, clinical safety labs and AEs, will be summarised. AEs were coded using the medical dictionary for regulatory activities, and data will be summarised by system organ class and preferred term.

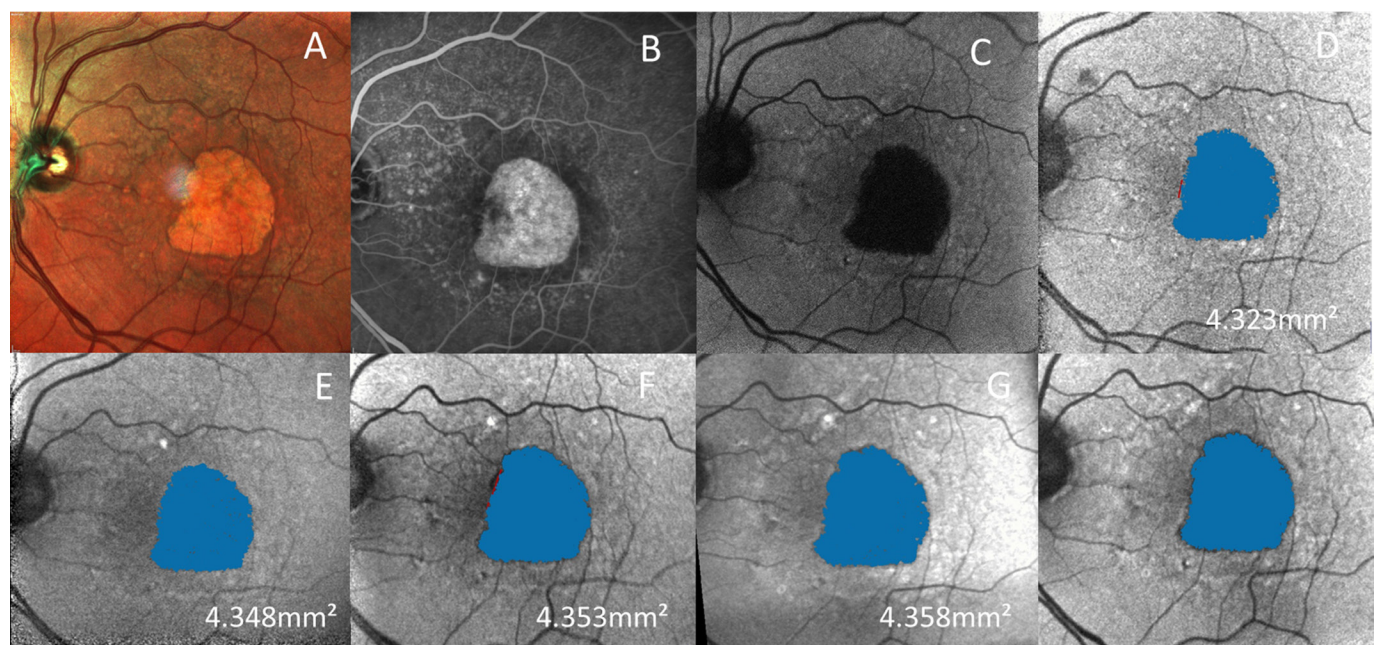


Figure 1 Example of atrophy as measured by Heidelberg region finder software (A) baseline multicolour, (B) baseline fluorescein angiogram, (C) baseline autofluorescence, (D) baseline region finder, (E) month 1, (F) month 2, (G) month 3 and (H) month 6.

Table 1 Baseline characteristics

Baseline characteristic	N=9
Age (years) mean±SD	79.73±6.19
Female	55.5%
Right eye	55.5%
Pseudophakic	55.5%
BCVA (letters) mean±SD	53.11±10.01
LLVA (letters) mean±SD	39.33±11.21
IOP Mean±SD	13.33±3.08
GA area (mm ²) mean±SD	9.53±5.69

BCVA, best-corrected visual acuity; GA, geographical atrophy; IOP, intraocular pressure; LLVA, low-luminance visual acuity.

RESULTS

Nine participants were enrolled in the study, baseline characteristics are presented in table 1. The mean age of participants was 79.7±6.2 years and 5 of 9 were female. Mean baseline BCVA and LL-BCVA were 53.1±10.0 and 39.3±11.2 letters, respectively. Mean baseline area of GA was 9.50±5.7 mm².

The initial pilot participant dosed with 1 mg/mL FCA experienced a loss of 22 letters (≥15 letters) at day 28, however this was deemed most likely unrelated to the IP by the DSMB as vision improved (+9 letters) on subsequent visit (day 60) and there were no signs of any other AEs or safety concerns.

One participant dosed with 2 mg/mL FCA experienced a nasal subconjunctival haemorrhage after day 90 in the study eye that resolved after 1 week. No other AEs were noted throughout the study.

No significant increases in IOP (≥10 mm Hg) were observed among any patients throughout the study. The mean change in IOP was -0.25 mm Hg (p=0.75) at day 150 compared with baseline (table 2). There were no significant changes in body temperature, heart rate, systolic or diastolic blood pressure throughout the study (p>0.05 for all).

Four of the nine patients (44.4%) had a natural lens; no formal grading of lens opacity was performed as part of the protocol. One participant had significant lens opacity at screening which did not hinder imaging, however no

participants required/underwent cataract surgery during the study period. No participants developed CNV during the study.

Progression of GA area

The mean area of GA increased in both the study (0.5 mm², p=0.003) and fellow (0.62 mm², p=0.02) eyes over the duration of the study. This translates to a mean reduction in progression rate of 19.9% over the duration of the study. The change in area was not significant between eyes (p=0.64) (table 2). There were no differences in progression rate among study eyes dosed with 1 mg or 2 mg FCA (p=0.41).

DISCUSSION

This study shows that IVT FCA is clinically safe and well tolerated among this cohort of patients with GA secondary to AMD. Raised IOP is a typical side effect of intraocular steroids and was not observed in this study. Increased lens opacity is another typical side effect, however, no participants required cataract surgery during the study. Furthermore, no systemic AE was observed during this does escalation study.

A recent meta-analysis of 23 studies reported the natural progression of GA lesions in untreated eyes to be 1.66 mm²/year.²¹ Results from the Proxima A and B clinical trials reported a growth rate of 2.09 and 1.90 mm²/year, respectively, over the first 12 months. Another study by Schmitz-Valckenberg *et al*²² reported a change of 0.88 mm² over 6 months. Our study findings indicate that GA progression was lower in both the treated (0.5 mm²) and fellow eyes (0.62 mm²) over the study period, suggesting a possible treatment effect of FCA. Both the GATHER one and Filly studies have reported a 20%–30% reduction the rate of GA progression over 12 months,²³ our findings report a similar rate of 19.9%.

Previous studies assessing the efficacy of complement inhibitors in reducing GA progression have found mild to moderate rates of conversion of GA to CNV. The GATHER one study (Zimura) reported CNV developing in 3.5% of study eyes and 2.7% of controls over a 12-month period.²⁴ The Filly study assess the safety and efficacy of Pegcetacoplan and reported conversion to CNV of 20.9% in the monthly arm, 8.9% in the bimonthly arm and 1.2% in the control arm over 12 months.²³ No eyes developed CNV

Table 2 Changes in characteristics from baseline

Variable	Study eye		Fellow eye		
	Mean change from baseline	P value	Mean change from baseline	P value	P value between eyes
BCVA (letters)	-2.63±7.01	0.28	4.88±8.37	0.69	0.07
LLVA (letters)	3.25±9.23	0.38	4.5±11.49	0.72	0.81
IOP (mm Hg)	-0.25±4.06	0.75	-0.625±4.24	0.69	0.86
GA area (mm ²)	0.5±5.69	0.003	0.62±4.49	0.02	0.64

BCVA, best-corrected visual acuity; GA, geographical atrophy; IOP, intraocular pressure; LLVA, low-luminance visual acuity.

in this study, however, participants were only followed-up for 150 days as part of the study.

LLVA is a known predictor of visual loss in patients with GA, where it can detect a change in central function earlier than standard VA assessments.^{25–27} Our findings show that LLVA did not deteriorate over the study period may be considered promising, and worthy of a more detailed study to be conducted in a larger cohort.

Previous studies assessing IVT glucocorticoid treatments have found improvements in the function of the blood retinal barrier.^{28,29} These findings are consistent with preclinical investigations into the use of FCA in vitro, and in vivo using a mouse model of AMD.⁵ In those experiments FCA was found to have potent anti-inflammatory effects and to be neuroprotective in the AMD model.

Clinical studies have previously reported previously that monocular treatments can affect fellow eyes,^{30–32} meaning that comparison of measures between treated and fellow eyes cannot serve as valid controls, and that population norms are the most useful comparators. Given that both the treated and fellow eyes showed a slower progression rate compared with previous reports, there may also be a similar sympathetic response in the fellow untreated eye.

The limitations of this study are the small sample size and the absence of formal lens grading, both of which were considered non-essential to the primary objective of this safety study. Another limitation of the study is its short duration. The strength of this study is its prospective design.

In summary, the data show that IVT FCA is clinically safe and well-tolerated among this cohort. Treatment with FCA did not increase IOP, further longer-term studies with larger sample size and multidose regimens may aid in assessing the efficacy of FCA in reducing GA progression.

Acknowledgements The authors and sponsors wish to acknowledge the contribution of the members of the DSMB namely: Dr Amy Pai MBBS, BSc (UNSW), PhD (USyd), FRANZCO. Dr Tim Schlub, Snr Lecturer in Biostatistics School of Public Health, University of Sydney.

Contributors TH was involved in the planning, design, conduct, acquisition, analysis and interpretation of the data. AC was involved in the conduct, acquisition and interpretation of the data. TM was involved in the planning, design, analysis and interpretation of the data. JP was involved in the planning, design, analysis and interpretation of the data. PP was involved in the planning, design, analysis and interpretation of the data.

Funding The authors have not declared a specific grant for this research from any funding agency in the public, commercial or not-for-profit sectors.

Competing interests TH: Consultant, Novartis. AC: Consultant, Alcon, Bayer, Novartis, Ocular Therapeutix, Roche. TM: Consultant, Eye Co. PP: Chief Scientist and Director, Eye Co. JP: Emeritas Professor ANU Medical School; Chair, Scientific Advisory Committee.

Patient and public involvement Patients and/or the public were not involved in the design, or conduct, or reporting, or dissemination plans of this research.

Patient consent for publication Consent obtained directly from patient(s)

Ethics approval This study involves human participants and was approved by Bellberry (2018-08-709). Participants gave informed consent to participate in the study before taking part.

Provenance and peer review Not commissioned; externally peer reviewed.

Data availability statement All data relevant to the study are included in the article or uploaded as online supplemental information. Not Applicable.

Open access This is an open access article distributed in accordance with the Creative Commons Attribution Non Commercial (CC BY-NC 4.0) license, which permits others to distribute, remix, adapt, build upon this work non-commercially, and license their derivative works on different terms, provided the original work is properly cited, appropriate credit is given, any changes made indicated, and the use is non-commercial. See: <http://creativecommons.org/licenses/by-nc/4.0/>.

ORCID iD

Thomas Hong <http://orcid.org/0000-0002-2899-8832>

REFERENCES

- Rittiphairoj T, Mir TA, Li T, et al. Intravitreal steroids for macular edema in diabetes. *Cochrane Database Syst Rev* 2020;11: Cd005656.
- Chatziralli I, Nicholson L, Sivaprasad S, et al. Intravitreal steroid and anti-vascular endothelial growth agents for the management of retinal vein occlusion: evidence from randomized trials. *Expert Opin Biol Ther* 2015;15:1685–97.
- Al-Kharsan H, Hariprasad SM, Singh SR, et al. Long-term outcomes after intravitreal dexamethasone treatment in steroid responders. *Acta Diabetol* 2019;56:675–80.
- Gomez-Sanchez CE, Kirk DN, Farrant RD, et al. 18-Substituted steroids: synthesis of 18-hydroxycortisol (11 beta,17 alpha,18,21-tetrahydroxy-4-pregnene-3,20-dione) and 18-hydroxycortisone (17 alpha,18,21-trihydroxy-4-pregnene-3,11,20-trione). *J Steroid Biochem* 1985;22:141–6.
- Racic T, Chang A, Fernando N, et al. Anti-inflammatory and neuroprotective properties of the corticosteroid fludrocortisone in retinal degeneration. *Exp Eye Res* 2021;212:108765.
- Kivilcim M, Peyman GA, Morales AM. Evaluation of the retinal toxicity of fludrocortisone acetate after intravitreal injection. *Investig Ophthalmol Vis Sci* 2006;47:4281.
- Mitchell P, Smith W, Attebo K, et al. Prevalence of age-related maculopathy in Australia. The blue mountains eye study. *Ophthalmology* 1995;102:1450–60.
- Klein R, Klein BE, Linton KL. Prevalence of age-related maculopathy. The Beaver dam eye study. *Ophthalmology* 1992;99:933–43.
- Klein R, Klein BEK, Tomany SC, et al. Ten-year incidence of age-related maculopathy and smoking and drinking: the Beaver dam eye study. *Am J Epidemiol* 2002;156:589–98.
- Michalska-Malecka K, Kabiesz A, Nowak M, et al. Age related macular degeneration – challenge for future: Pathogenesis and new perspectives for the treatment. *Eur Geriatr Med* 2015;6:69–75.
- Holz FG, Strauss EC, Schmitz-Valckenberg S, et al. Geographic atrophy: clinical features and potential therapeutic approaches. *Ophthalmology* 2014;121:1079–91.
- Coleman HR, Chan C-C, Ferris FL, et al. Age-related macular degeneration. *Lancet* 2008;372:1835–45.
- Klein R, Klein BEK, Knudtson MD, et al. Fifteen-year cumulative incidence of age-related macular degeneration: the Beaver dam eye study. *Ophthalmology* 2007;114:253–62.
- Klein R, Cruickshanks KJ, Nash SD, et al. The prevalence of age-related macular degeneration and associated risk factors. *Arch Ophthalmol* 2010;128:750–8.
- Chong EW-T, Wong TY, Kreis AJ, et al. Dietary antioxidants and primary prevention of age related macular degeneration: systematic review and meta-analysis. *BMJ* 2007;335:755.
- Ding X, Patel M, Chan C-C. Molecular pathology of age-related macular degeneration. *Prog Retin Eye Res* 2009;28:1–18.
- Dastgheib K, Green WR. Granulomatous reaction to Bruch's membrane in age-related macular degeneration. *Arch Ophthalmol* 1994;112:813–8.
- Penfold PL, Wong JG, Gyory J, et al. Effects of triamcinolone acetonide on microglial morphology and quantitative expression of MHC-II in exudative age-related macular degeneration. *Clin Exp Ophthalmol* 2001;29:188–92.
- Krogh Nielsen M, Subhi Y, Molbech CR, et al. Systemic levels of interleukin-6 correlate with progression rate of geographic atrophy secondary to age-related macular degeneration. *Invest Ophthalmol Vis Sci* 2019;60:202–8.
- Tao Y, Jonas JB. Intravitreal triamcinolone. *Ophthalmologica* 2011;225:1–20.
- Wang J, Ying G-S. Growth rate of geographic atrophy secondary to age-related macular degeneration: a meta-analysis of natural history



- studies and implications for designing future trials. *Ophthalmic Res* 2021;64:205–15.
- 22 Schmitz-Valckenberg S, Sahel J-A, Danis R, *et al*. Natural history of geographic atrophy progression secondary to age-related macular degeneration (geographic atrophy progression study). *Ophthalmology* 2016;123:361–8.
- 23 Samanta A, Aziz AA, Jhingan M, *et al*. Emerging therapies in Nonexudative age-related macular degeneration in 2020. *Asia Pac J Ophthalmol* 2021;10:408–16.
- 24 Jaffe GJ, Westby K, Csaky KG, *et al*. C5 inhibitor Avacincaptad pegol for geographic atrophy due to age-related macular degeneration: a randomized pivotal phase 2/3 trial. *Ophthalmology* 2021;128:576–86.
- 25 Wood LJ, Jolly JK, Buckley TM, *et al*. Low luminance visual acuity as a clinical measure and clinical trial outcome measure: a scoping review. *Ophthalmic Physiol Opt* 2021;41:213–23.
- 26 Sunness JS, Rubin GS, Broman A, *et al*. Low luminance visual dysfunction as a predictor of subsequent visual acuity loss from geographic atrophy in age-related macular degeneration. *Ophthalmology* 2008;115:1480–8.
- 27 Wu Z, Ayton LN, Luu CD, *et al*. Longitudinal changes in microperimetry and low luminance visual acuity in age-related macular degeneration. *JAMA Ophthalmol* 2015;133:442–8.
- 28 van der Wijk A-E, Canning P, van Heijningen RP, *et al*. Glucocorticoids exert differential effects on the endothelium in an in vitro model of the blood-retinal barrier. *Acta Ophthalmol* 2019;97:214–24.
- 29 Lee JY, Eun CK, Kim YW, *et al*. The steroid effect on the blood-ocular barrier change induced by triolein emulsion as seen on contrast-enhanced Mr images. *Korean J Radiol* 2008;9:205–11.
- 30 Aghayeva FA, Chronopoulos P, Schuster AK, *et al*. Inter-Eye relationship of intraocular pressure change after unilateral trabeculectomy, filtering canaloplasty, or PreserFlo™ microshunt implantation. *Graefes Arch Clin Exp Ophthalmol* 2021;259:3045–53.
- 31 Gibbens MV. Sympathetic influences on the consensual ophthalmotonic reaction. *Br J Ophthalmol* 1988;72:750–3.
- 32 Rao HL, Senthil S, Garudadri CS. Contralateral intraocular pressure lowering effect of prostaglandin analogues. *Indian J Ophthalmol* 2014;62:575–9.